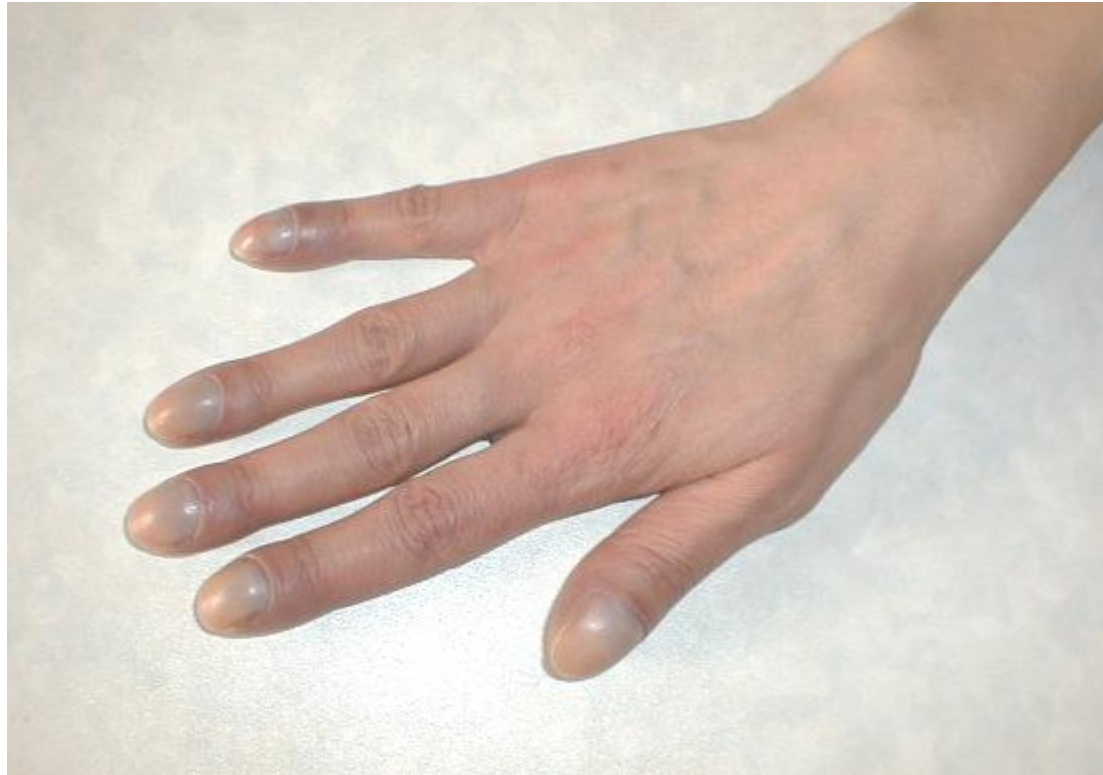

# Respiratory Examination

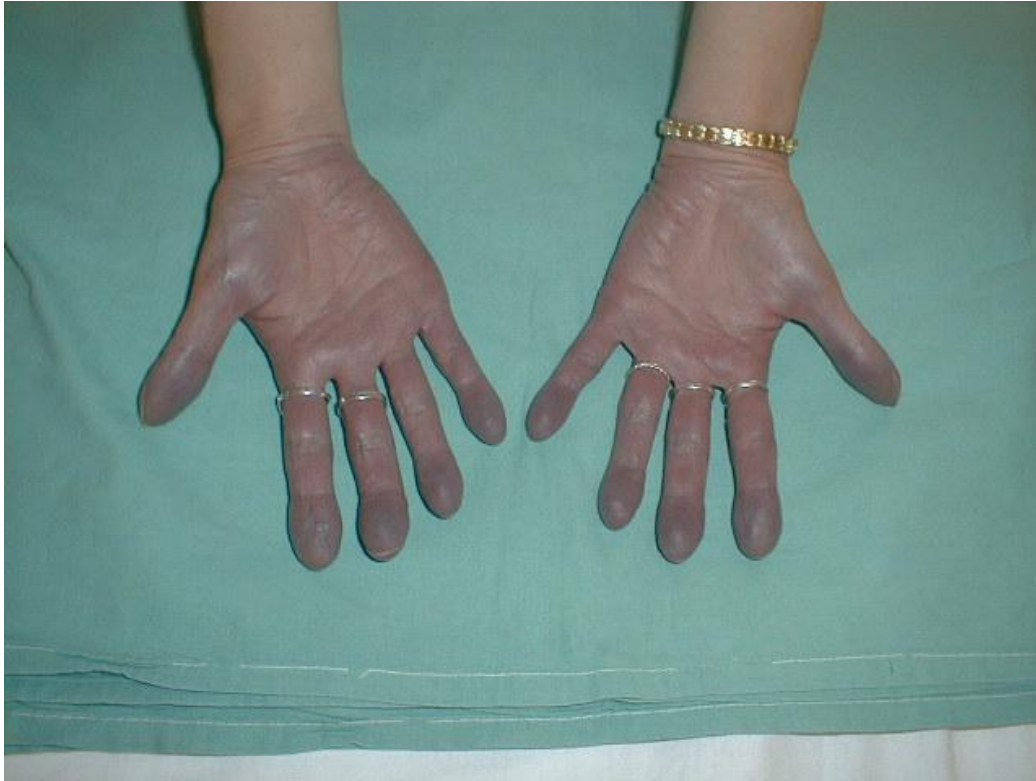A clinical atlas

# Hands and upper limbs

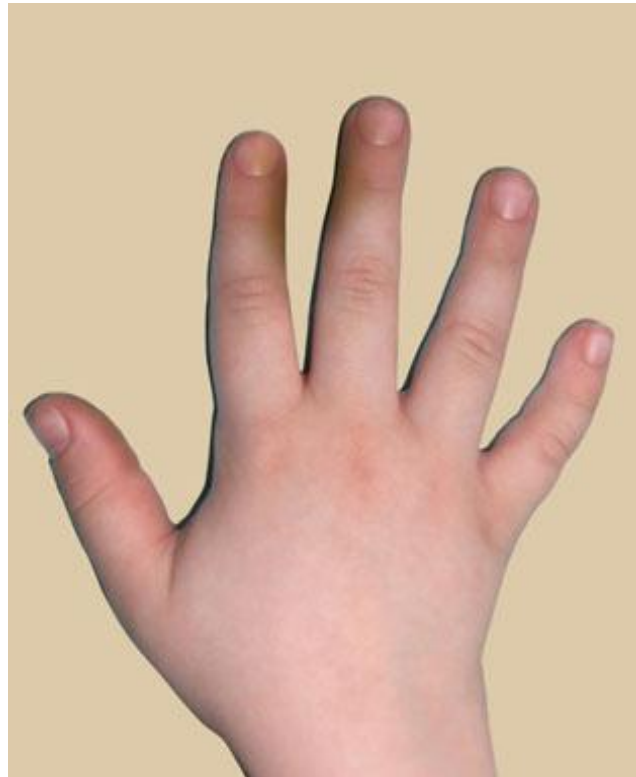# Clubbing



# Peripheral cyanosis and clubbing



# Tar staining



# Wasting of the intrinsic muscles of the hand

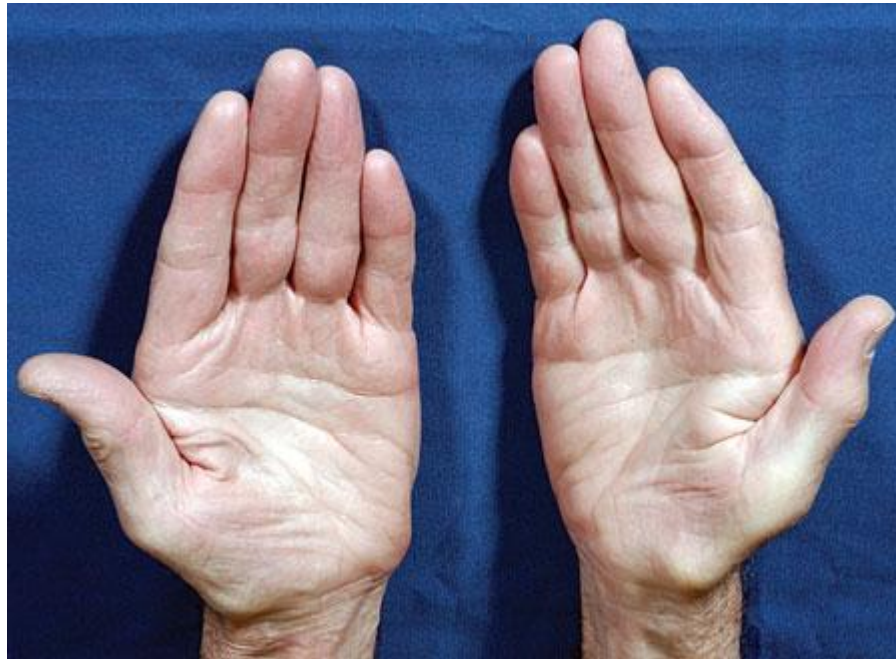
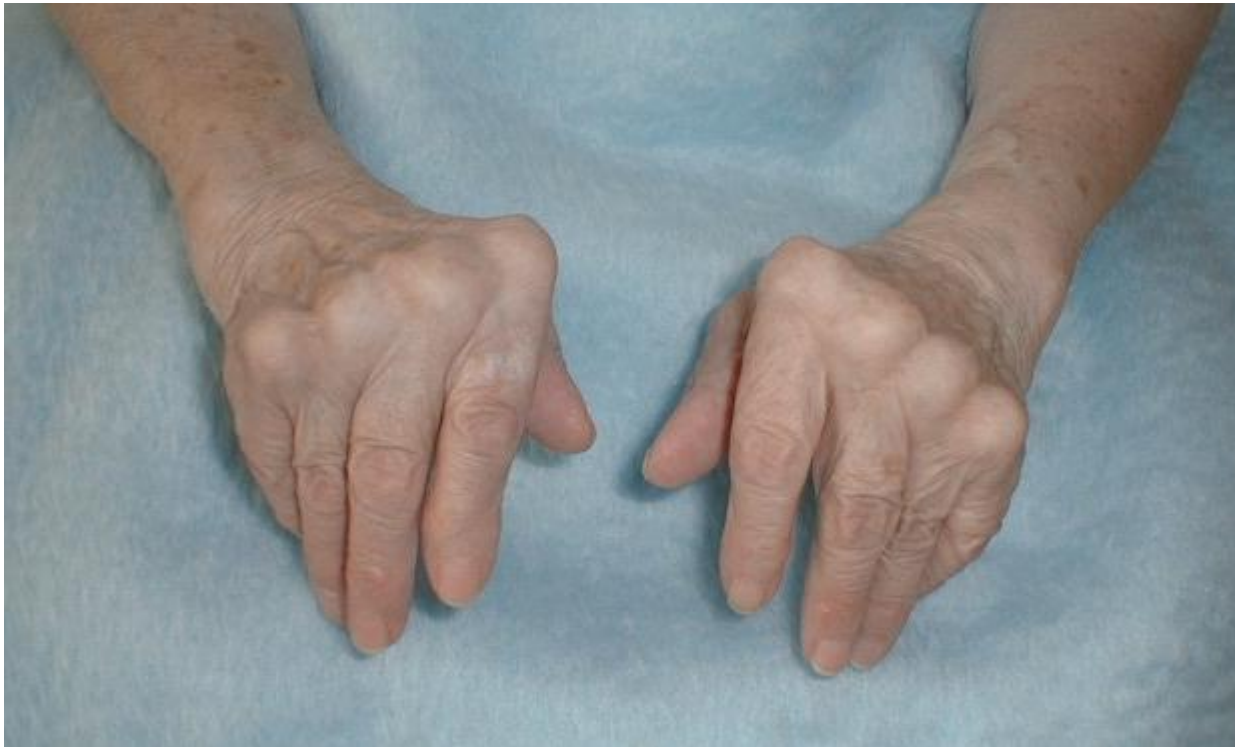
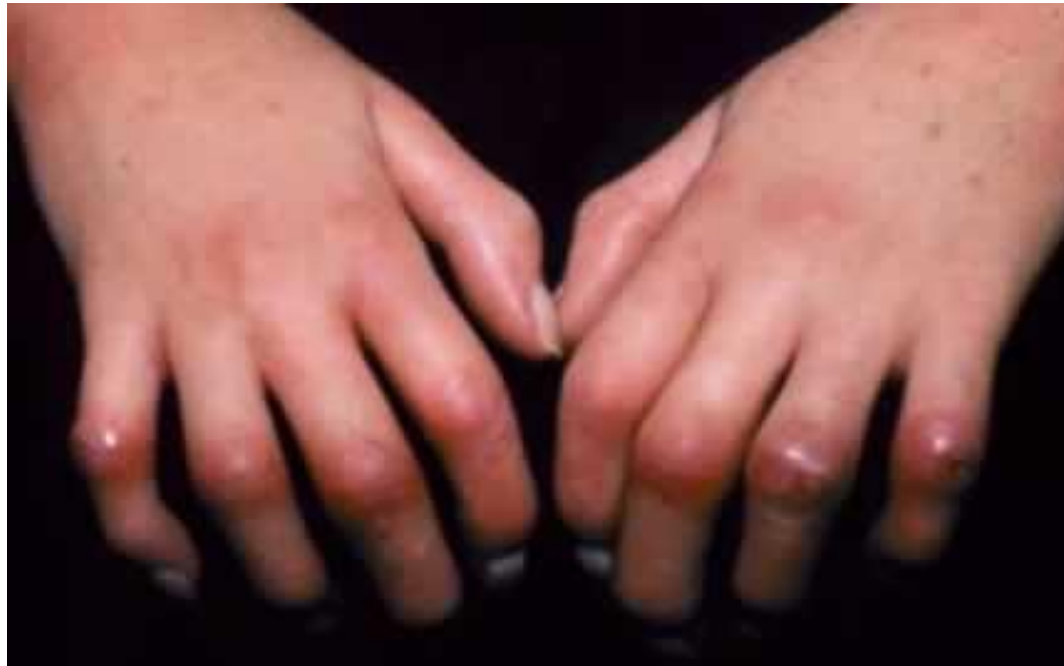Image taken from the following article:  
Neurological complications of Chronic Kidney Disease; Arun V. Krishnan & Matthew C. Kiernan  
*Nature Reviews Neurology* 5, 542-551 (October 2009) doi:10.1038/nrneurol.2009.138

# Rheumatoid hands

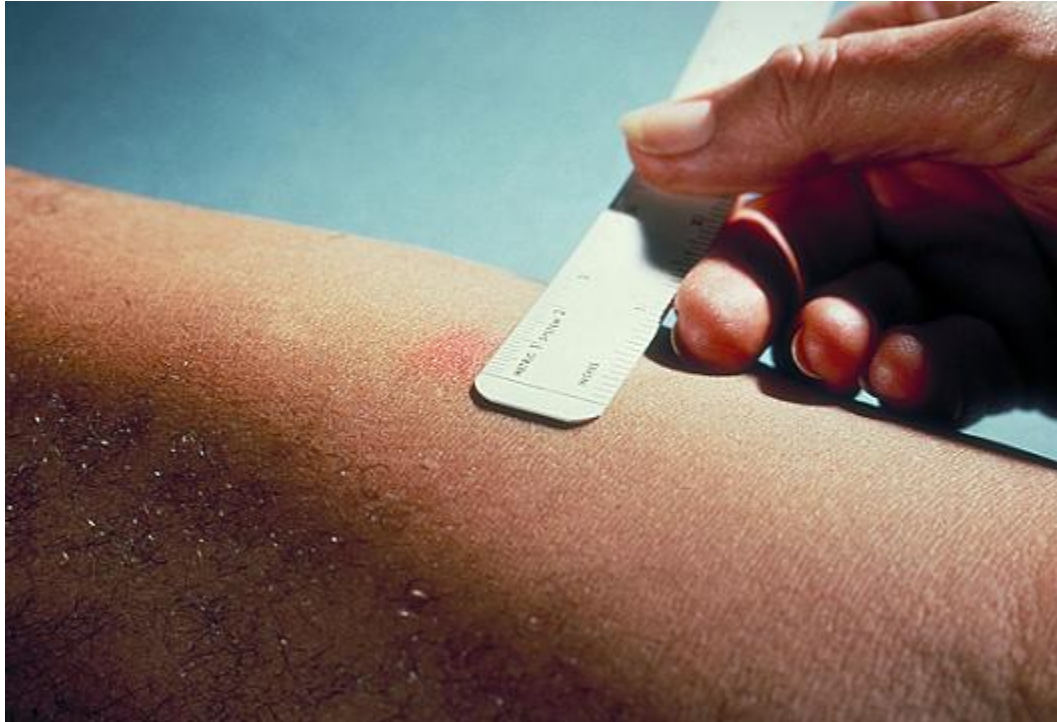

# Scleroderma



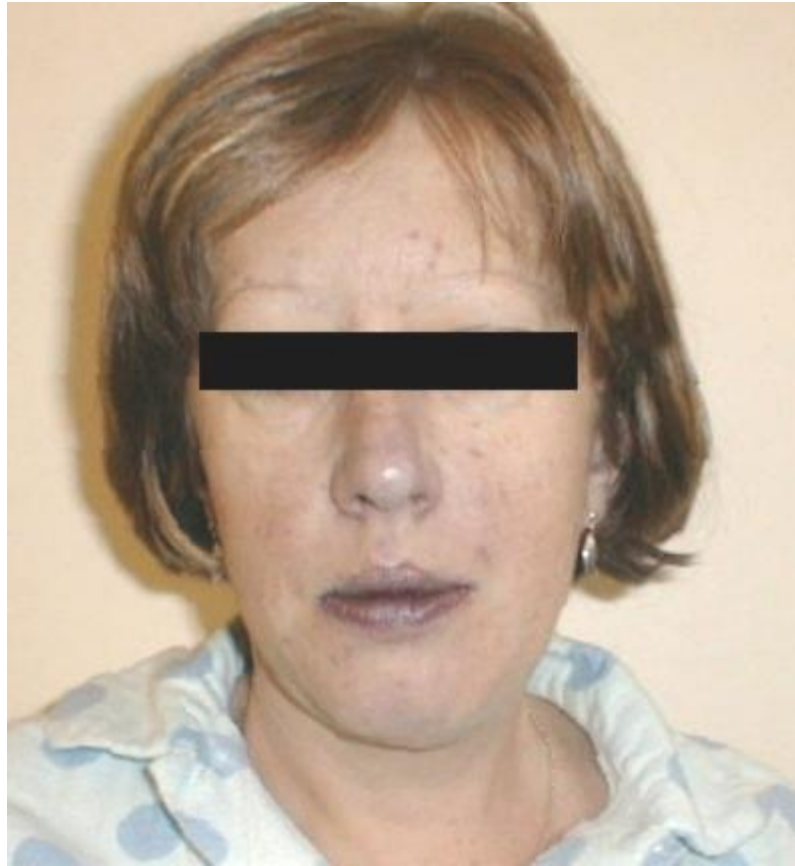

# Mantoux test

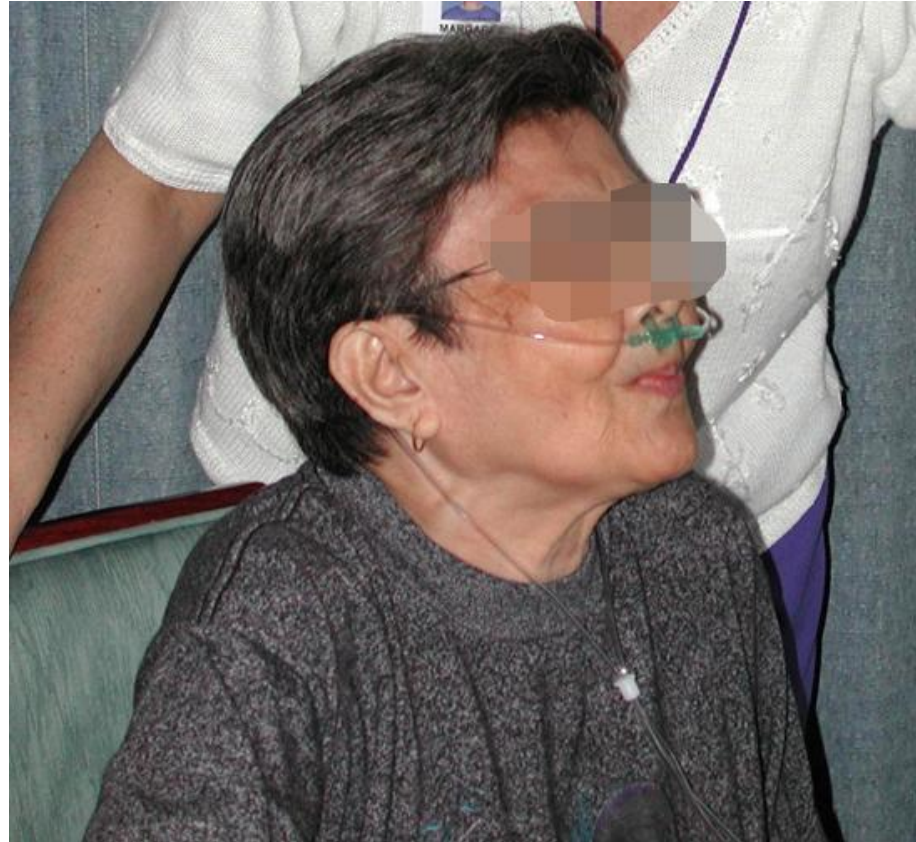

Face and neck

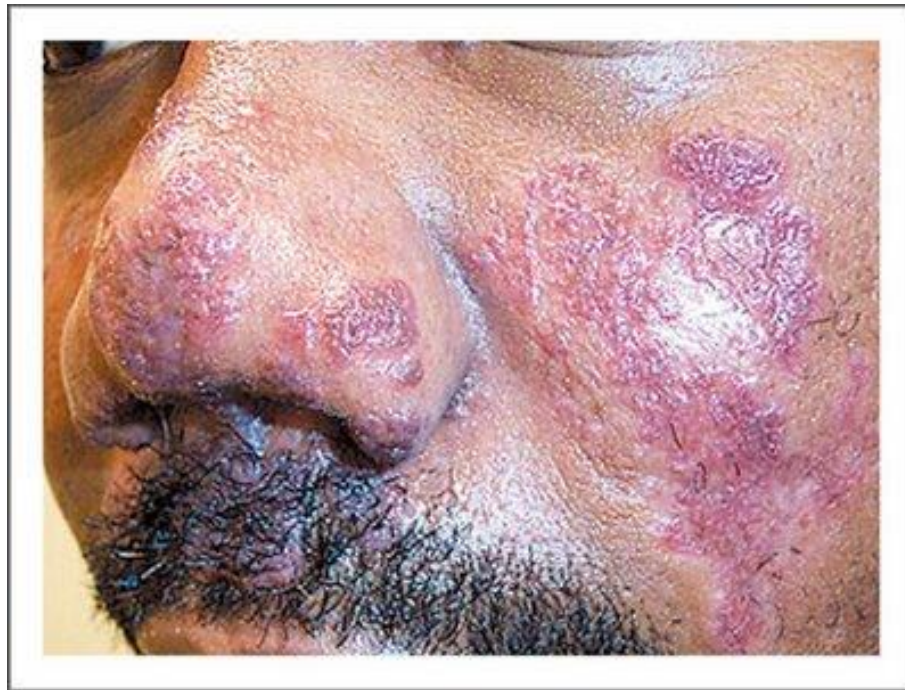# Central cyanosis



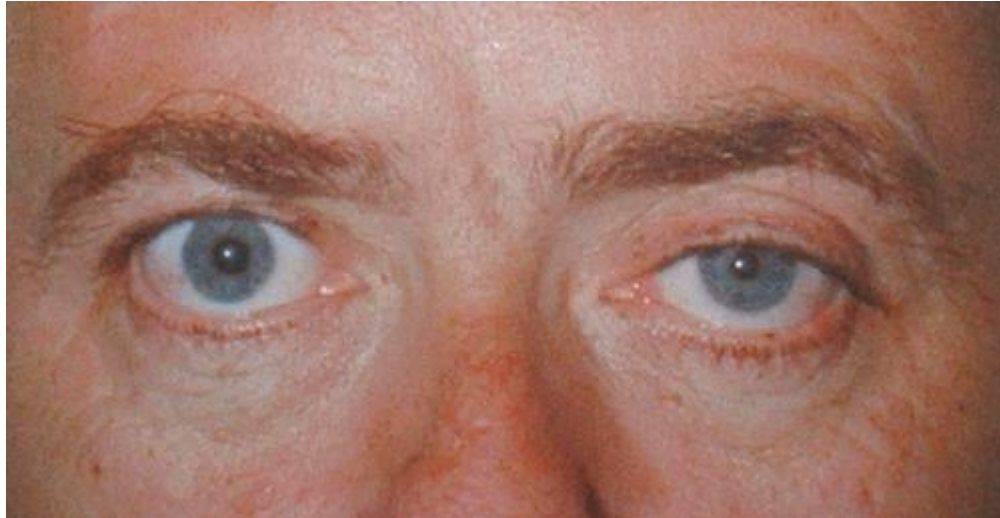# Purse lip breathing



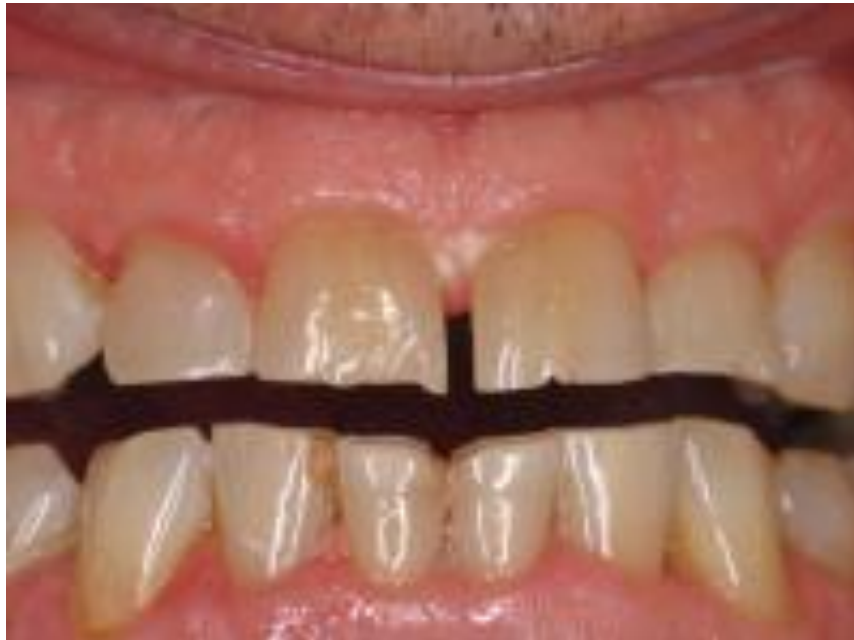# Lupus pernio



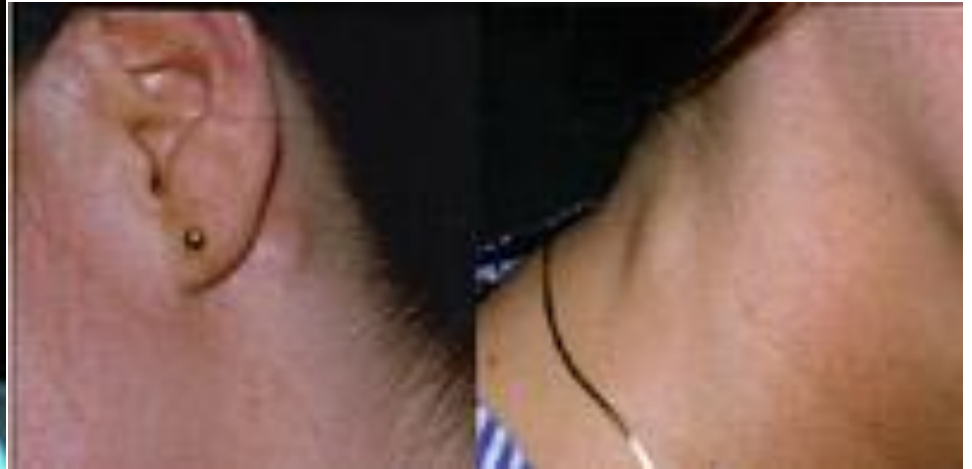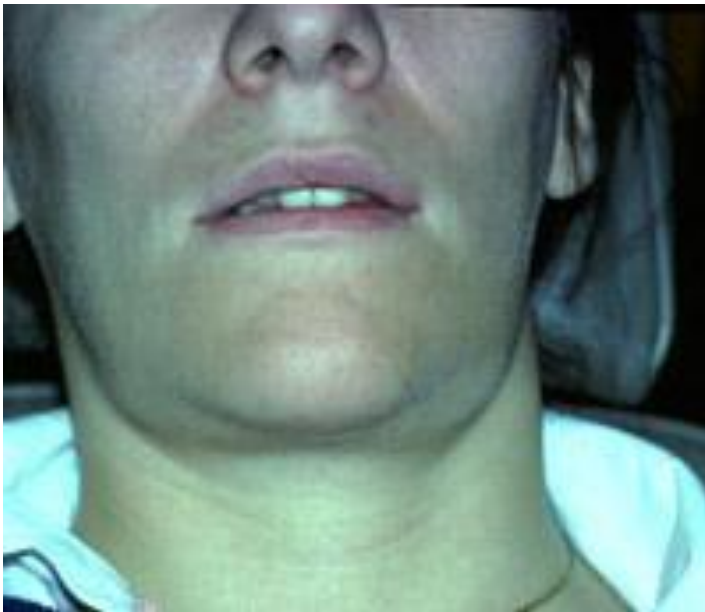
# Horners syndrome



# Tar stained Teeth

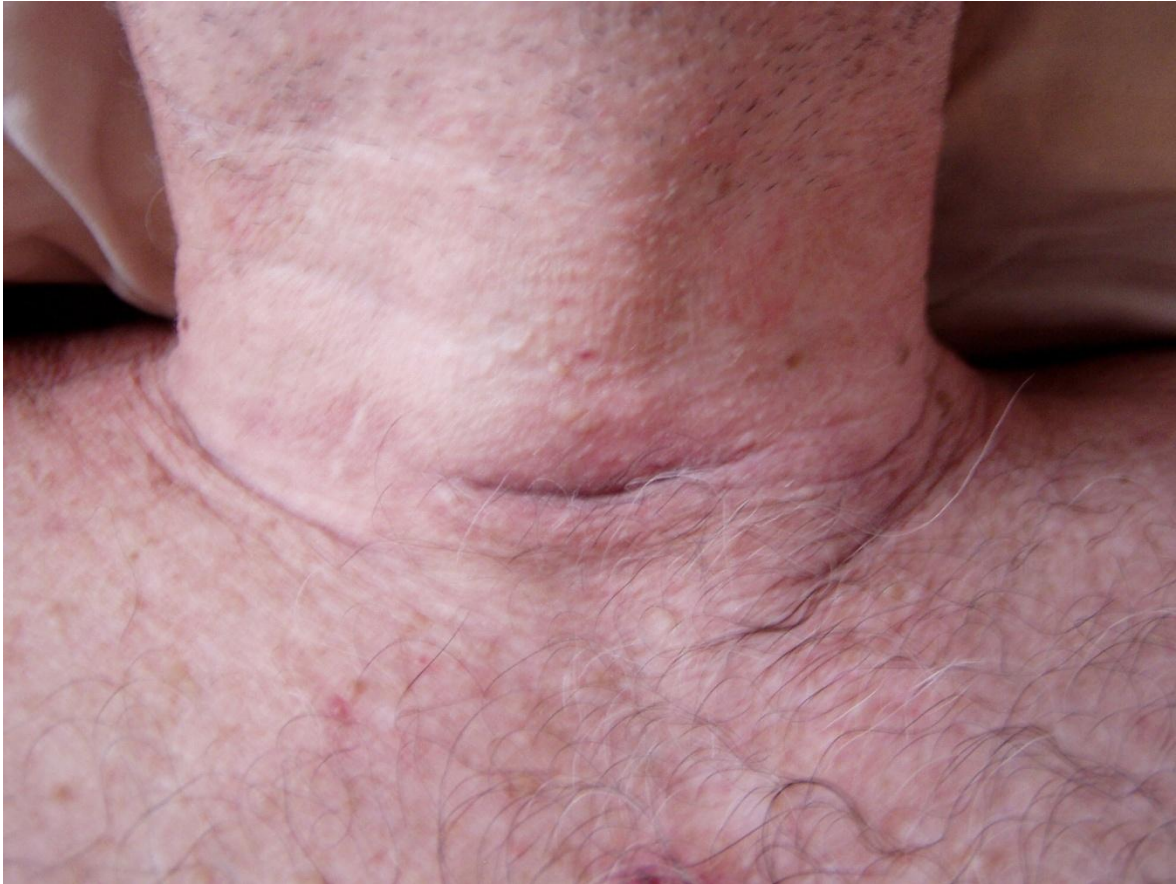

# Cervical lymphadenopathy



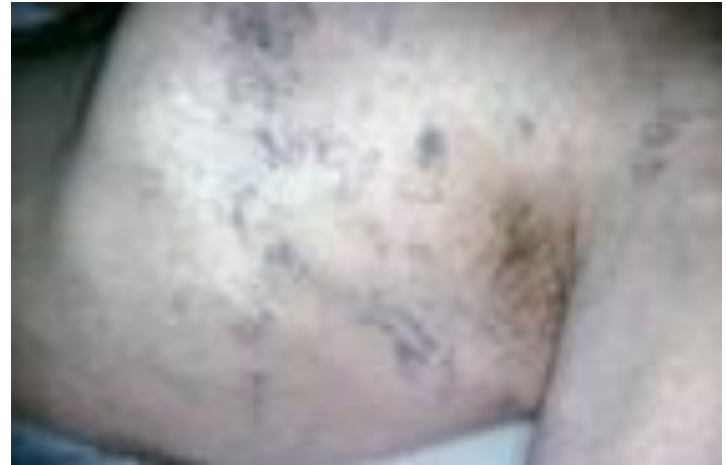
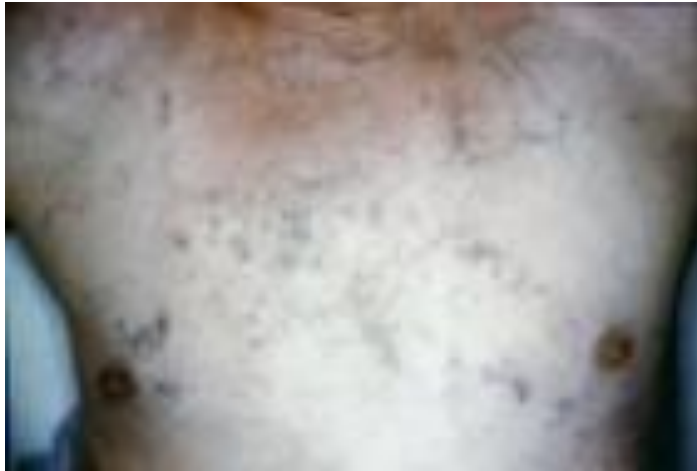
# Tracheostomy scar

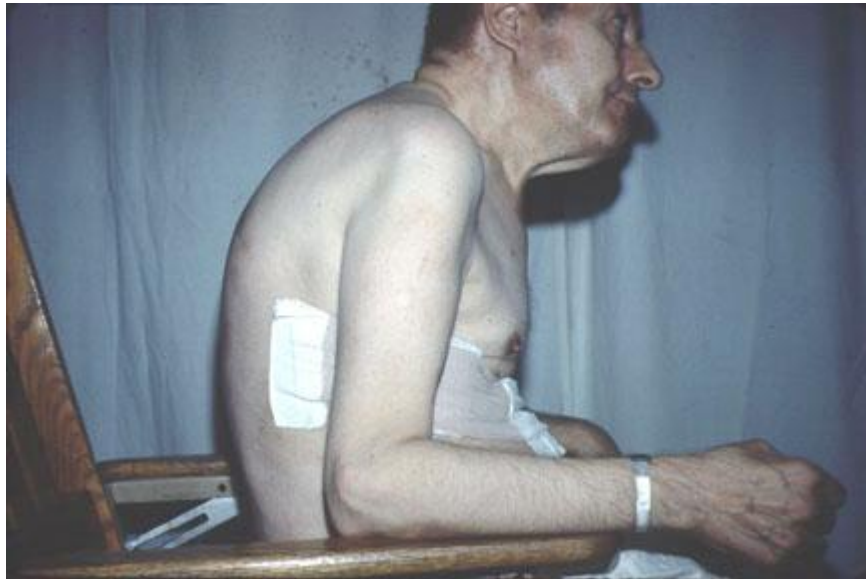

Thorax

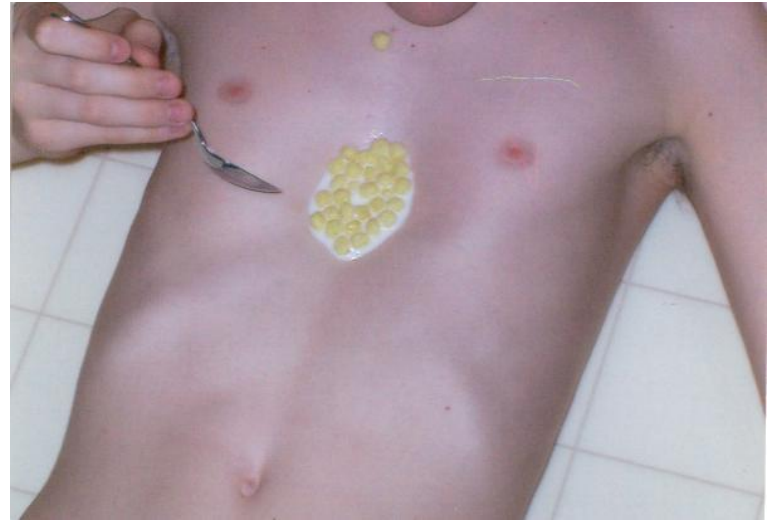
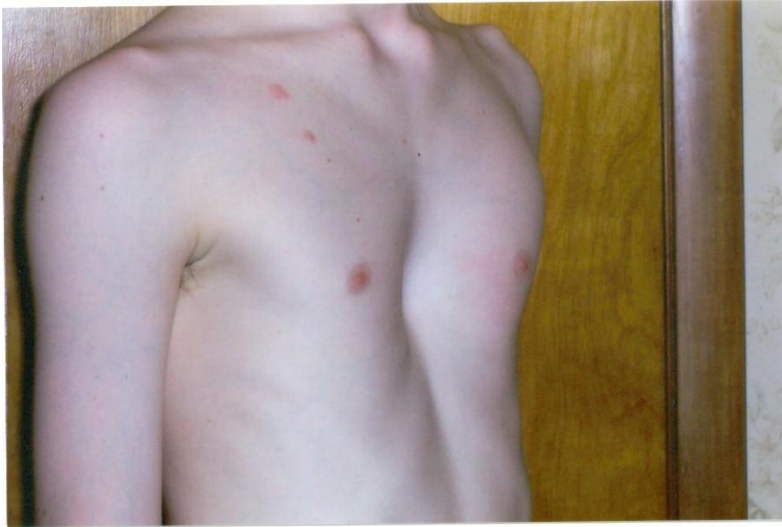# Superior Vena Caval Obstruction



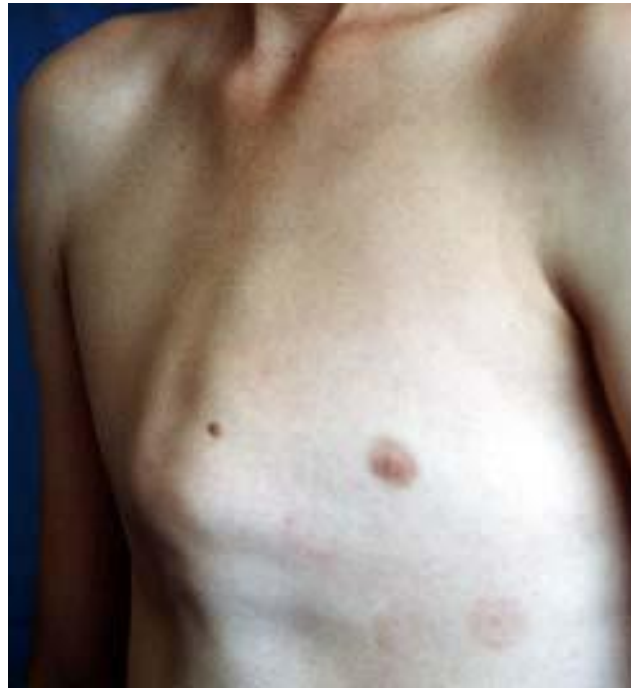# Hyperexpanded chest



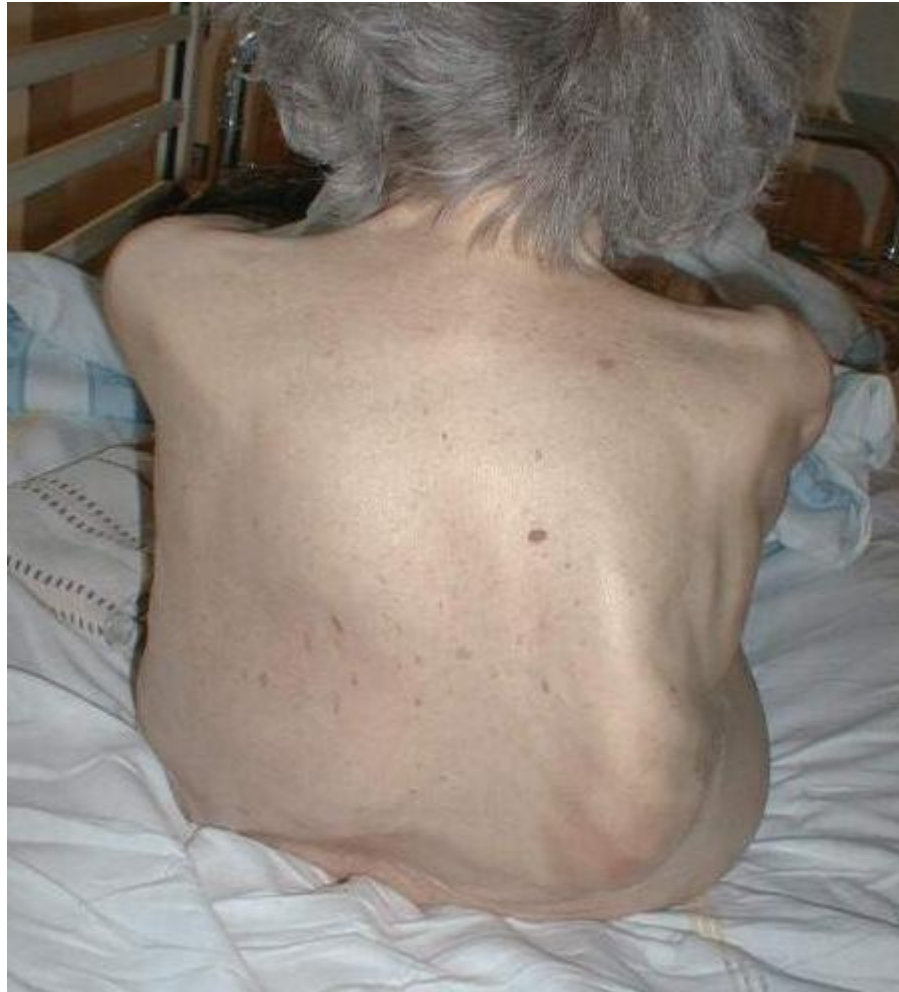# Pectus excavatum



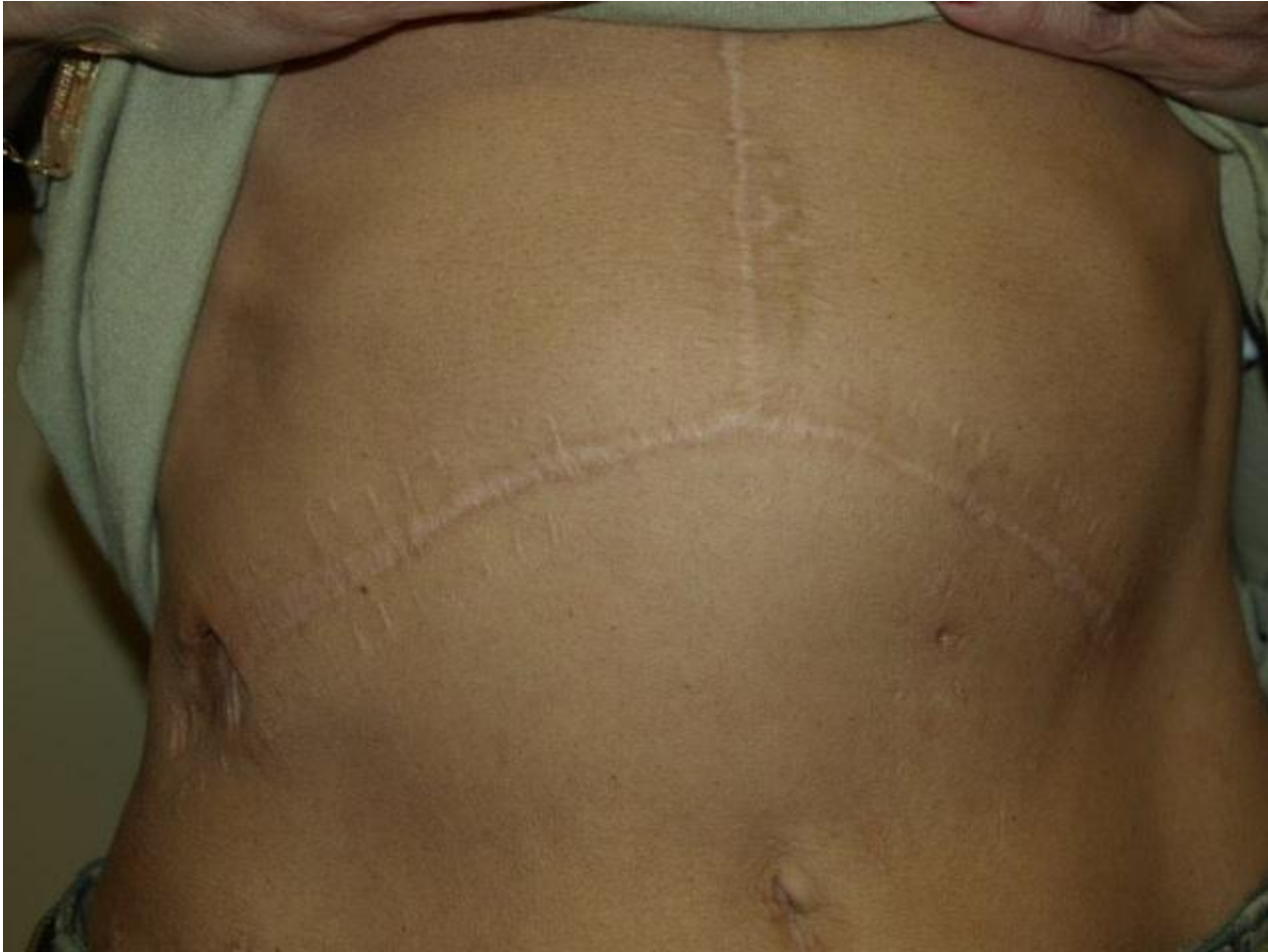# Pectus carinatum



# Kyphoscoliosis

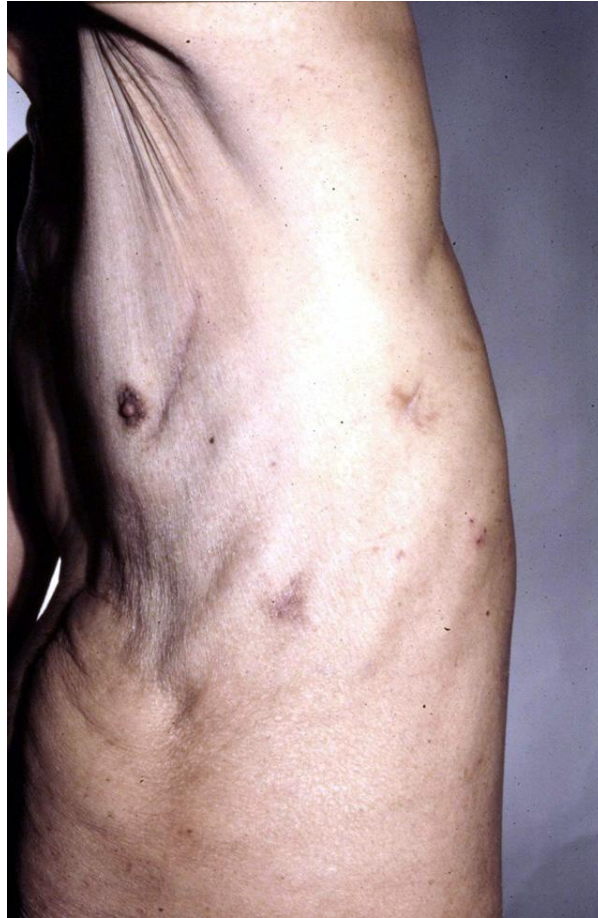

# Mercedes Benz Scar

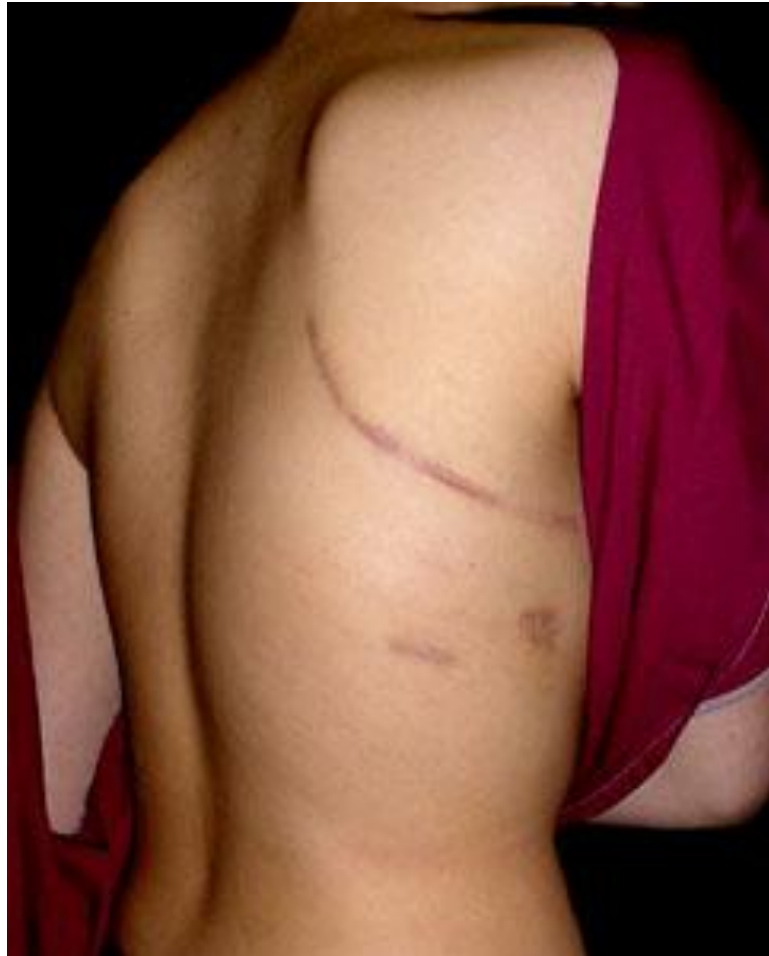



# Video Assisted Thorascopic Surgery scar

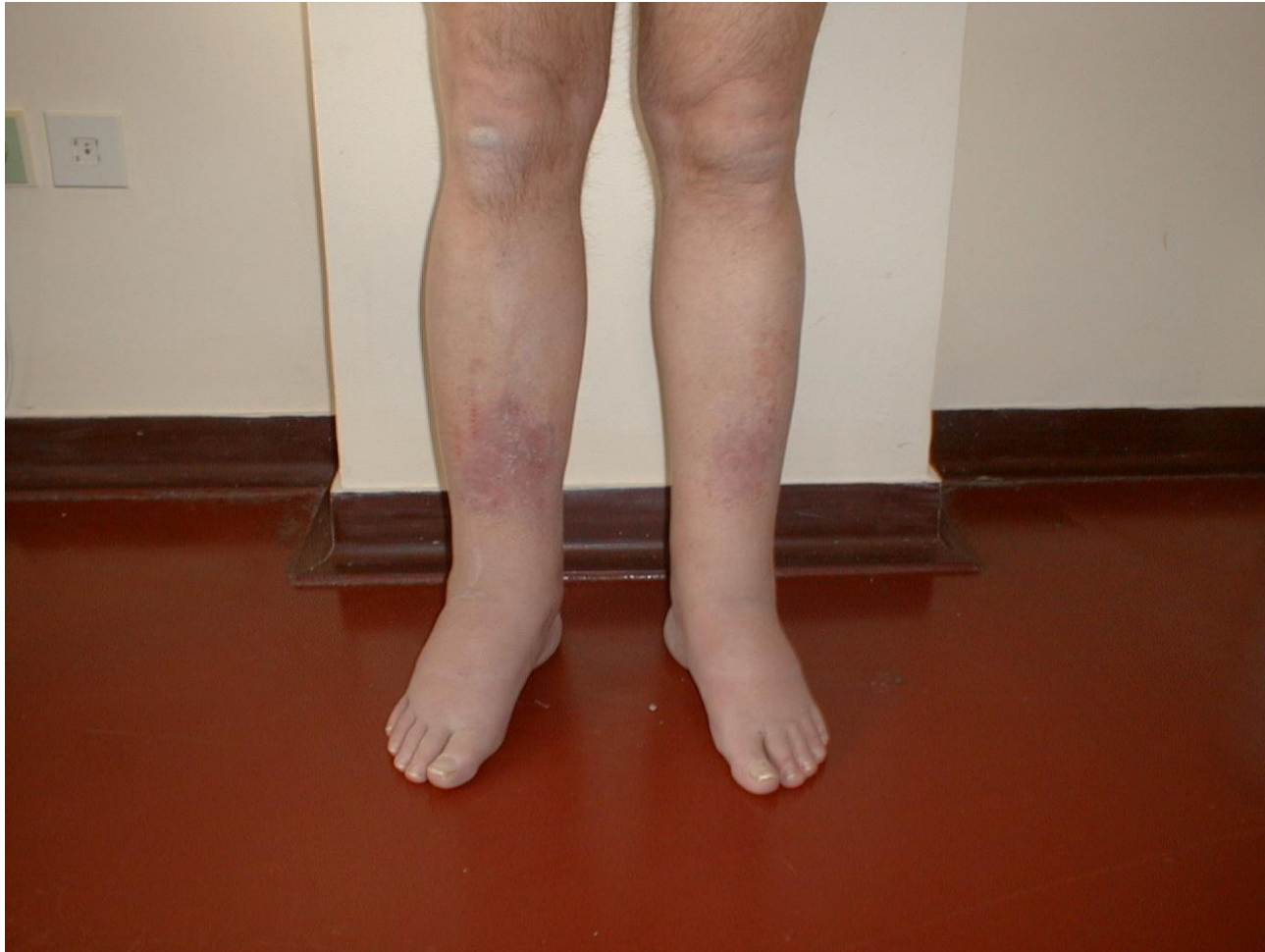

# Thoracotomy Scar



Lower limbs

# Peripheral oedema



# Miscellanea

# Plombage

