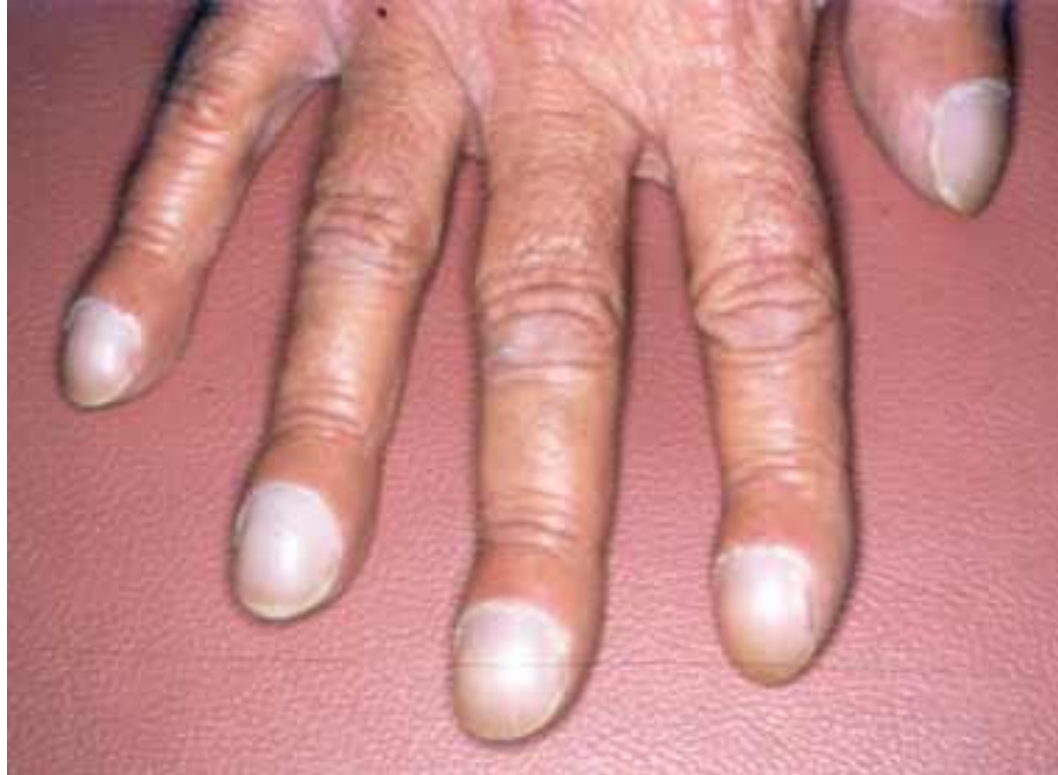

Cardiovascular examination

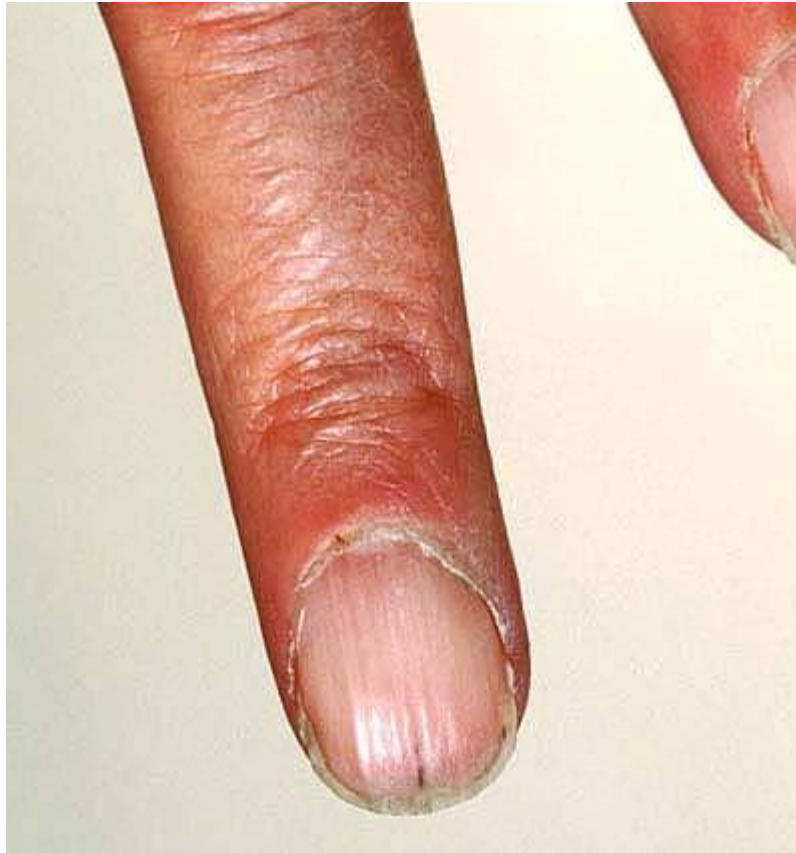A Clinical Atlas

Hands and upper limbs

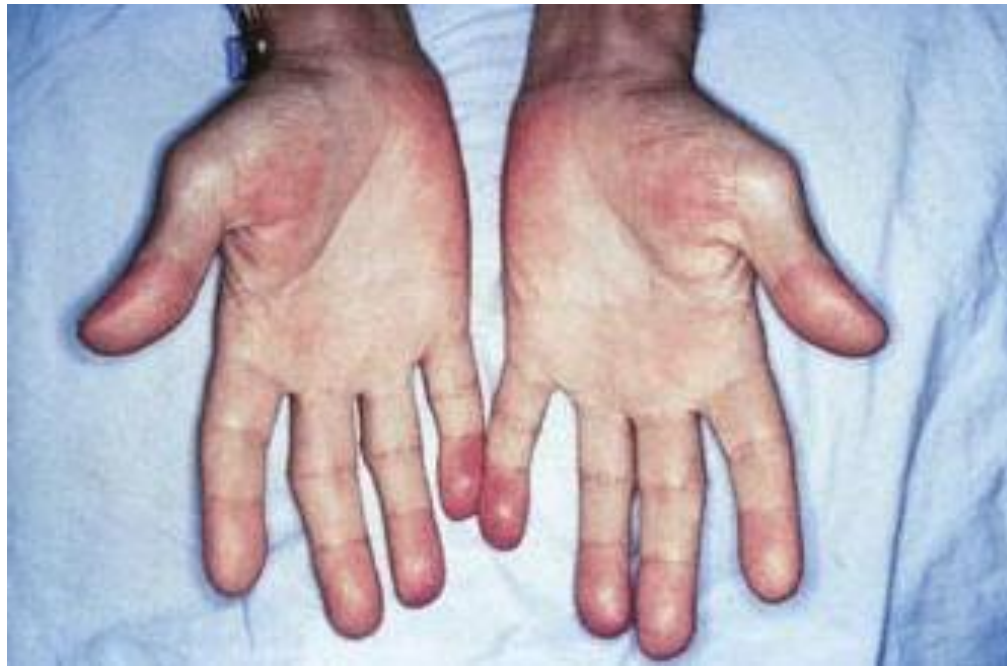Clubbing



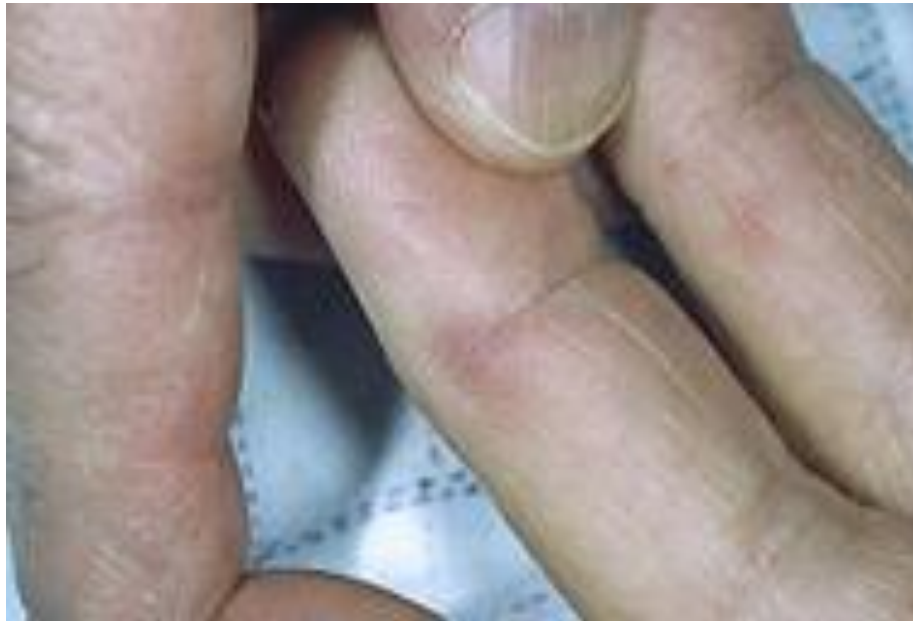Splinter Haemorrhages



Osler nodes (tender)



Janeway lesions



Images reproduced with permission: Charlie Goldberg, M.D., UCSD School of Medicine and VA Medical Center, San Diego, CA

Tendon Xanthoma

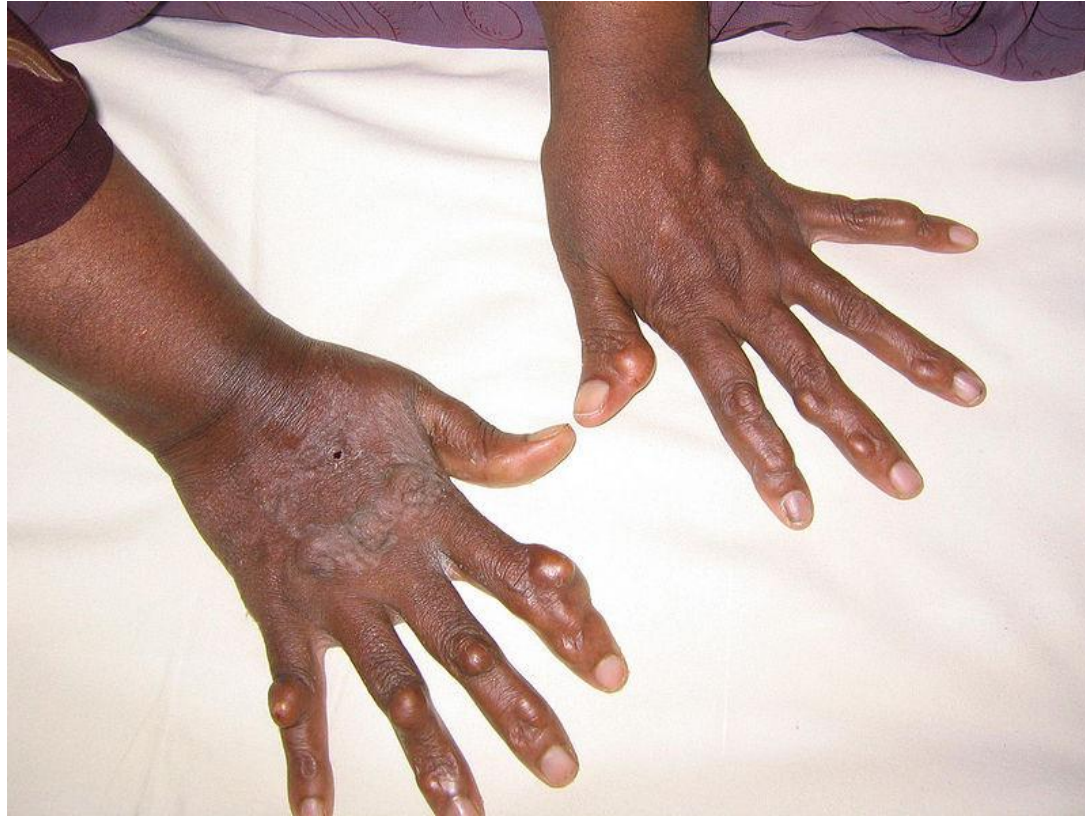
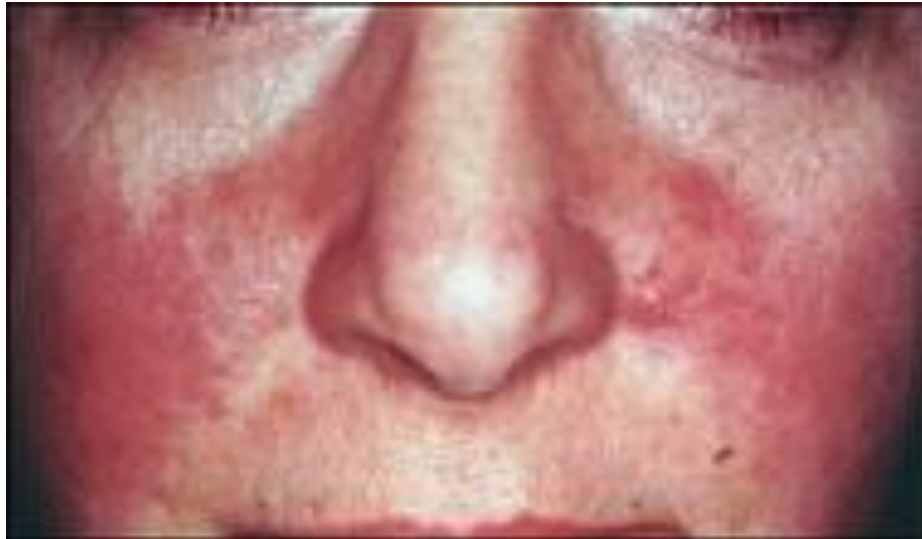
Image reproduced from:

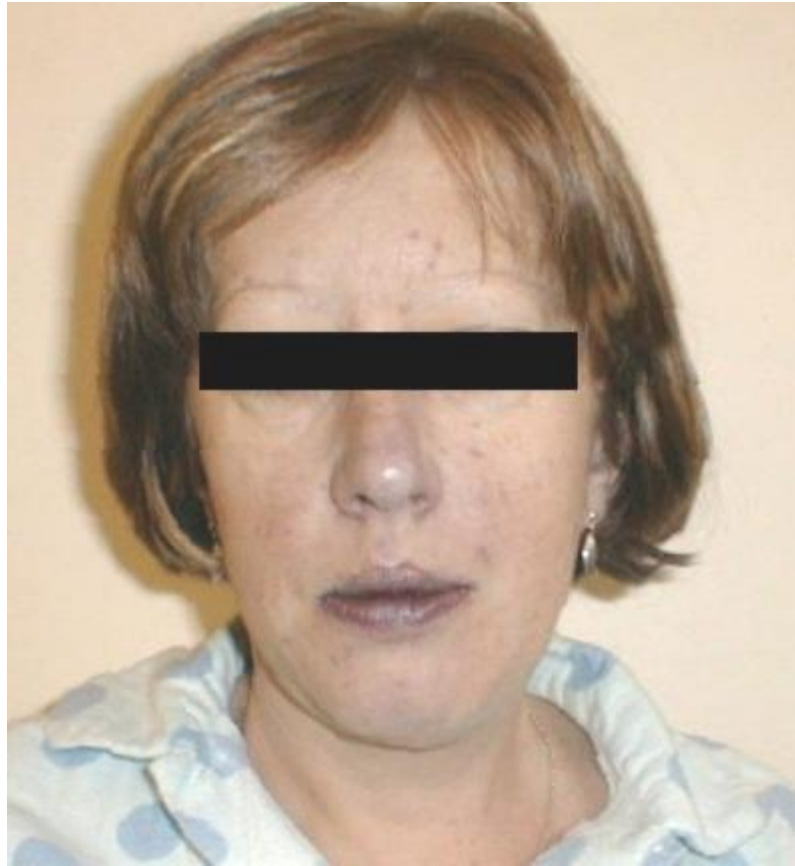Kumar et al. Cases Journal 2008 1:71 doi:10.1186/1757-1626-1-71

Face and neck

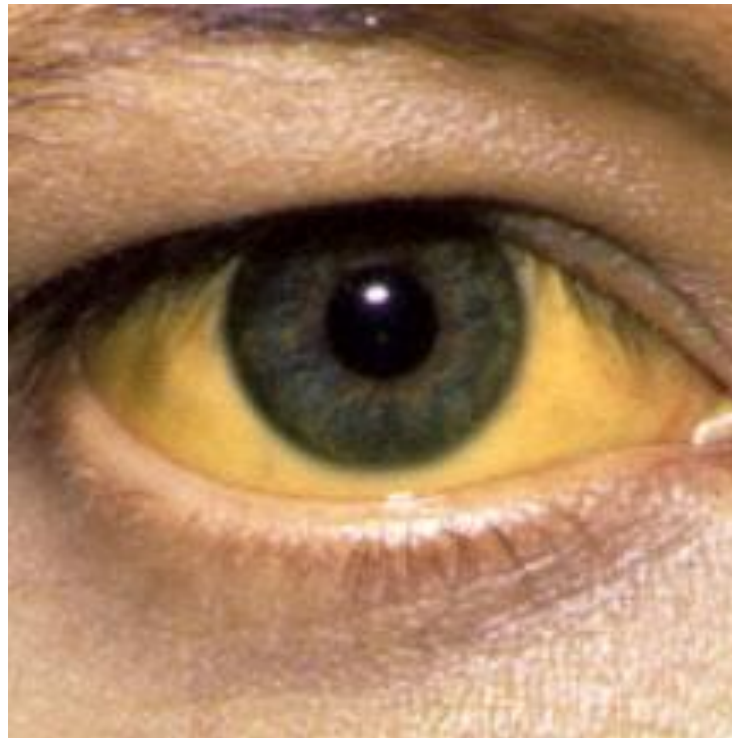
Malar flush



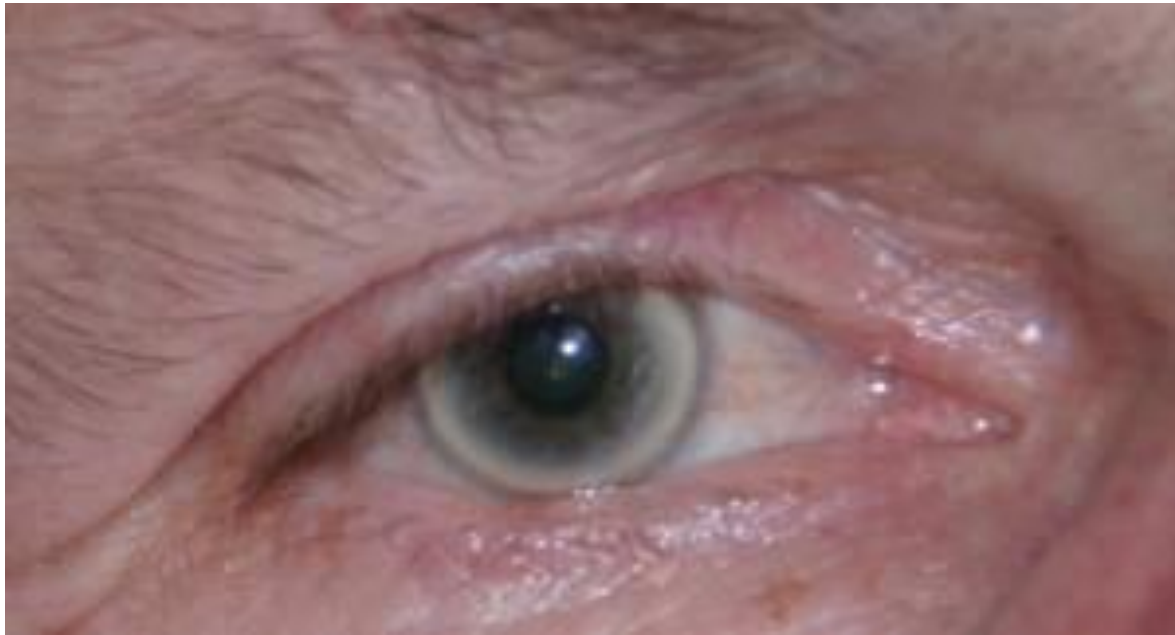
Central cyanosis



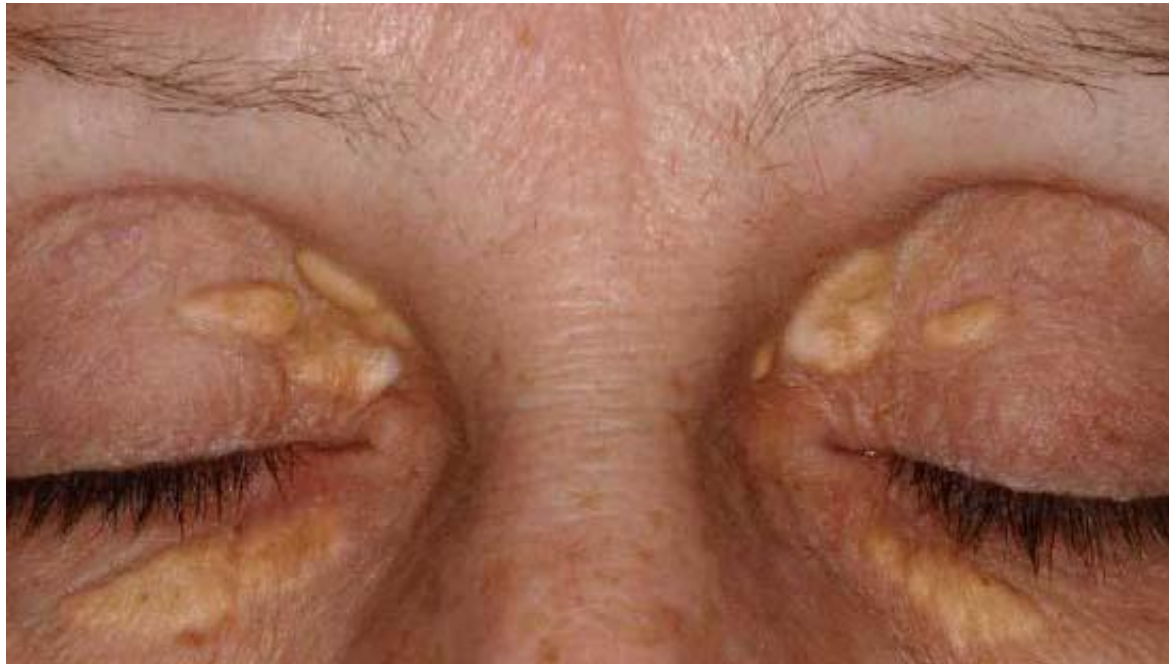Jaundiced sclera



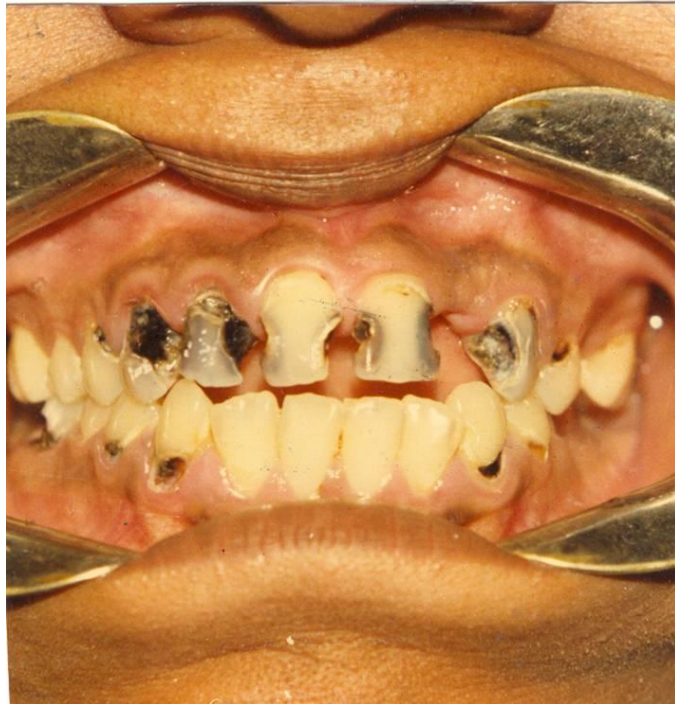Corneal Arcus



Xanthelasma



Poor oral hygiene



Franks sign

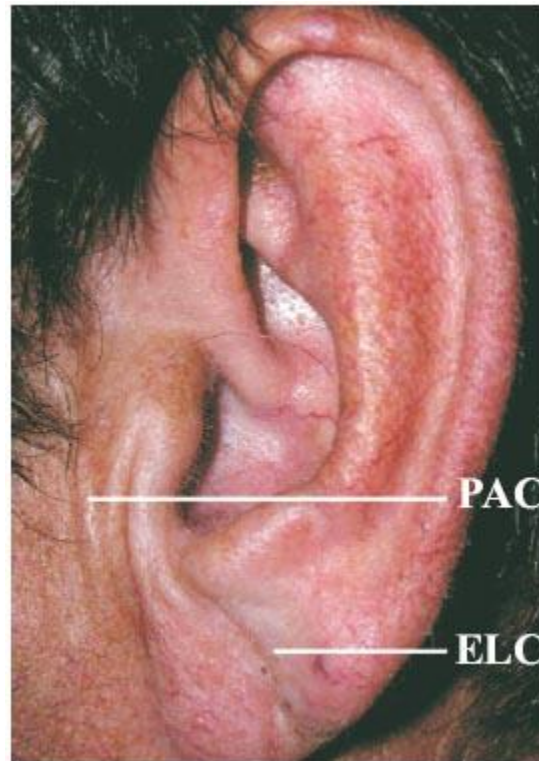


FIGURE 1: Diagonal ear-lobe crease (ELC) and preauricular crease (PAC)

Raised internal jugular vein

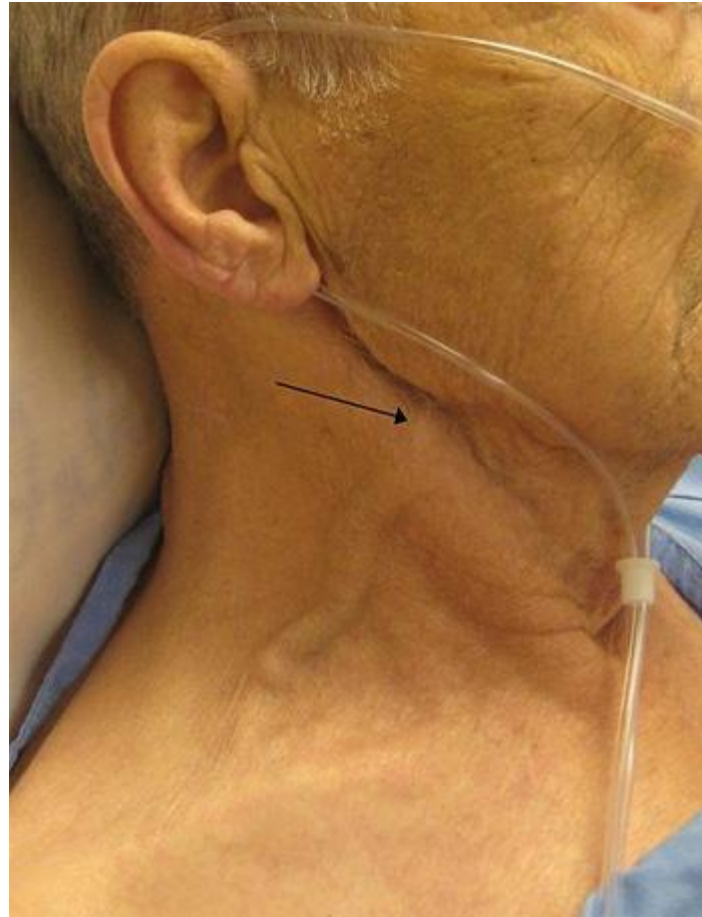
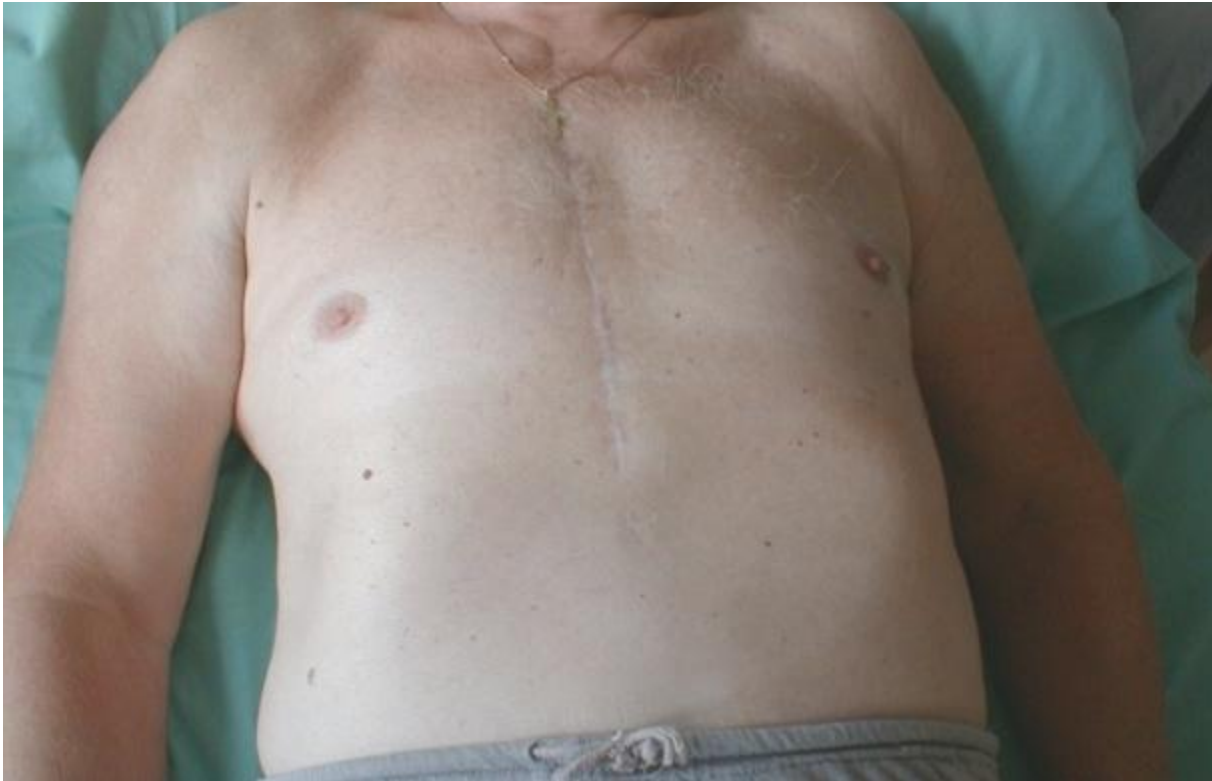
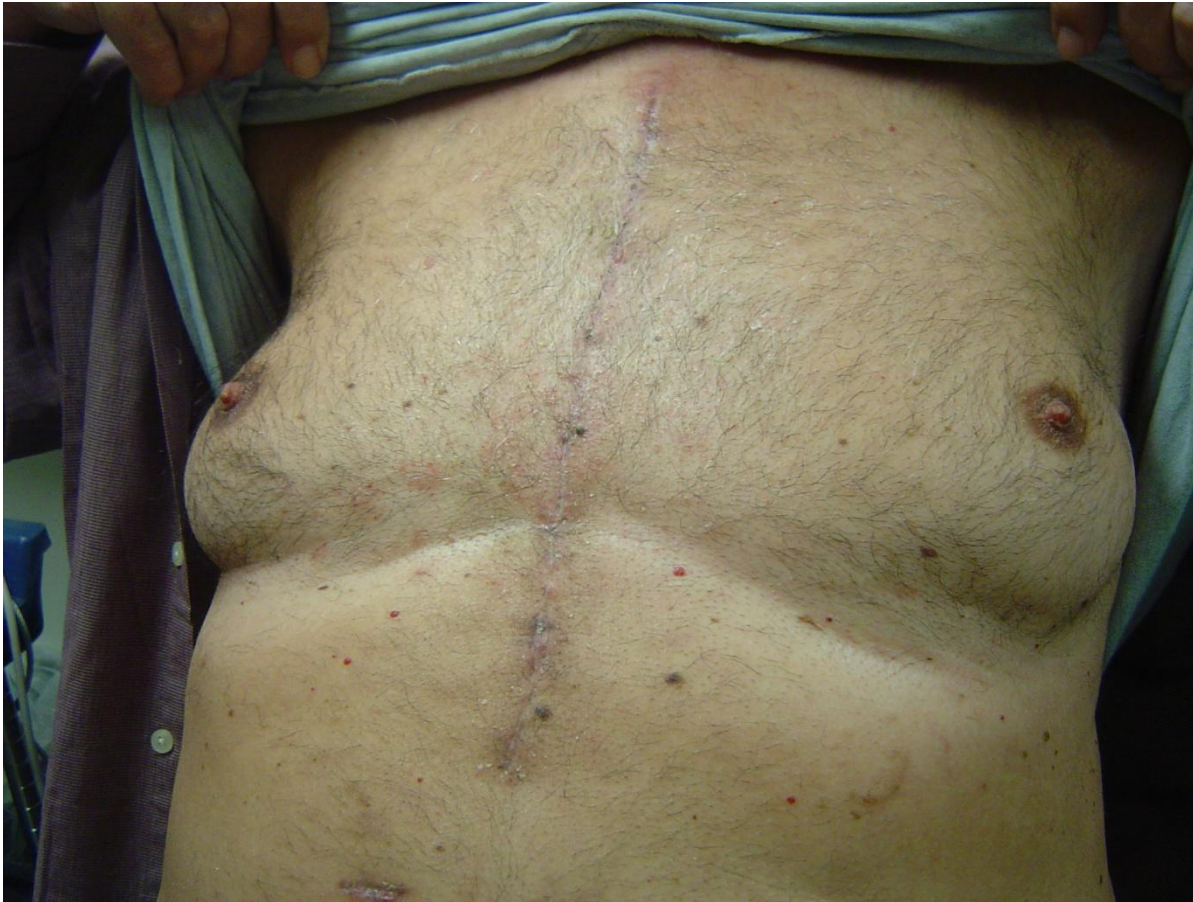Image from James Heilman MD reproduced from Wikipedia.en with permission

Midline sternotomy scar

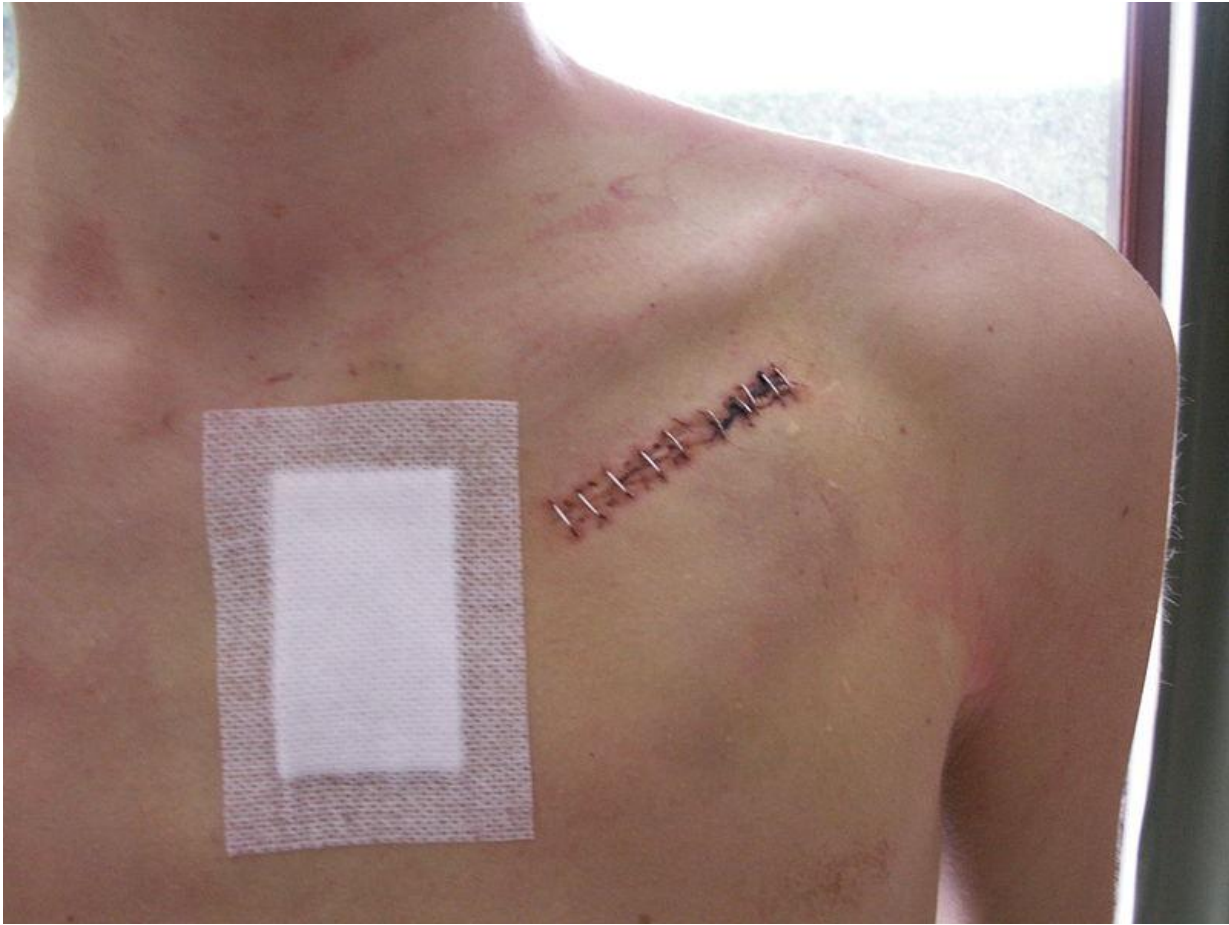

Thorax

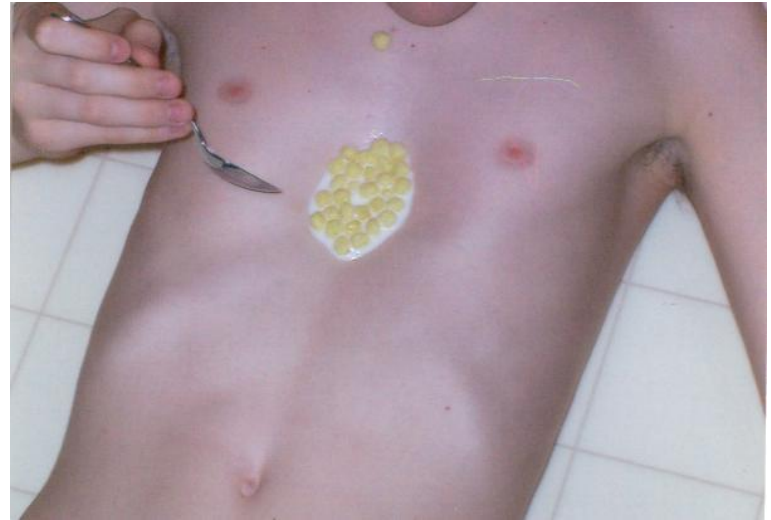
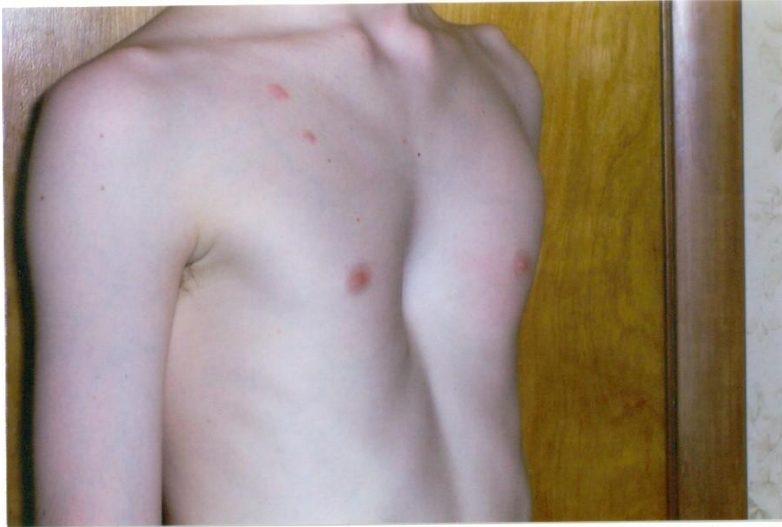Median sternotomy scar



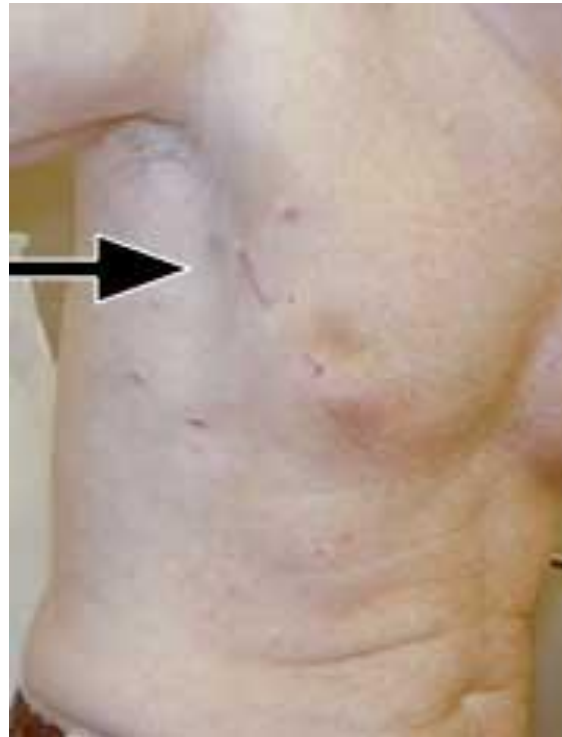Pacemaker



Pectus excavatum

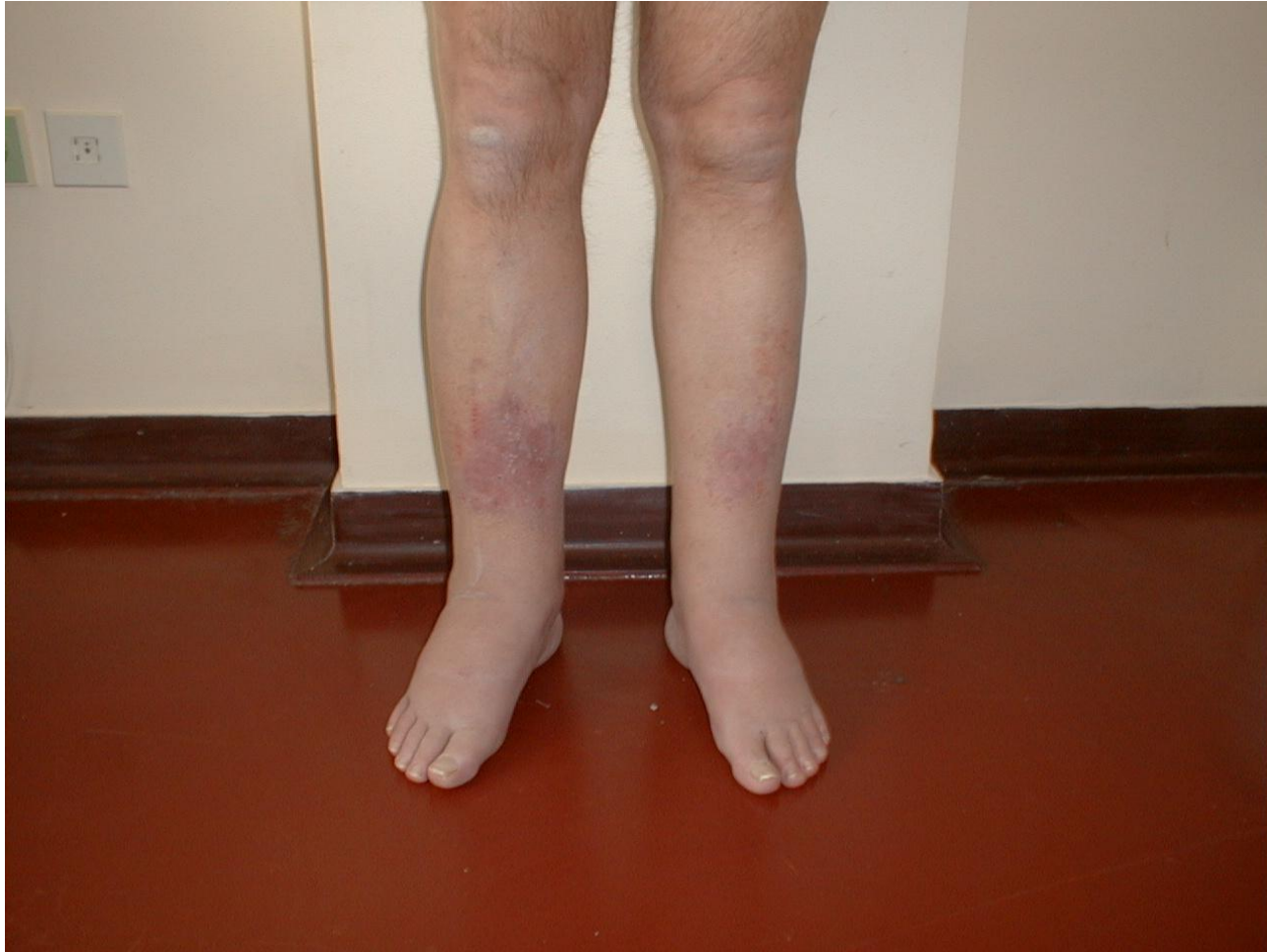

Minimally Invasive Mitral Valve Repair Scar

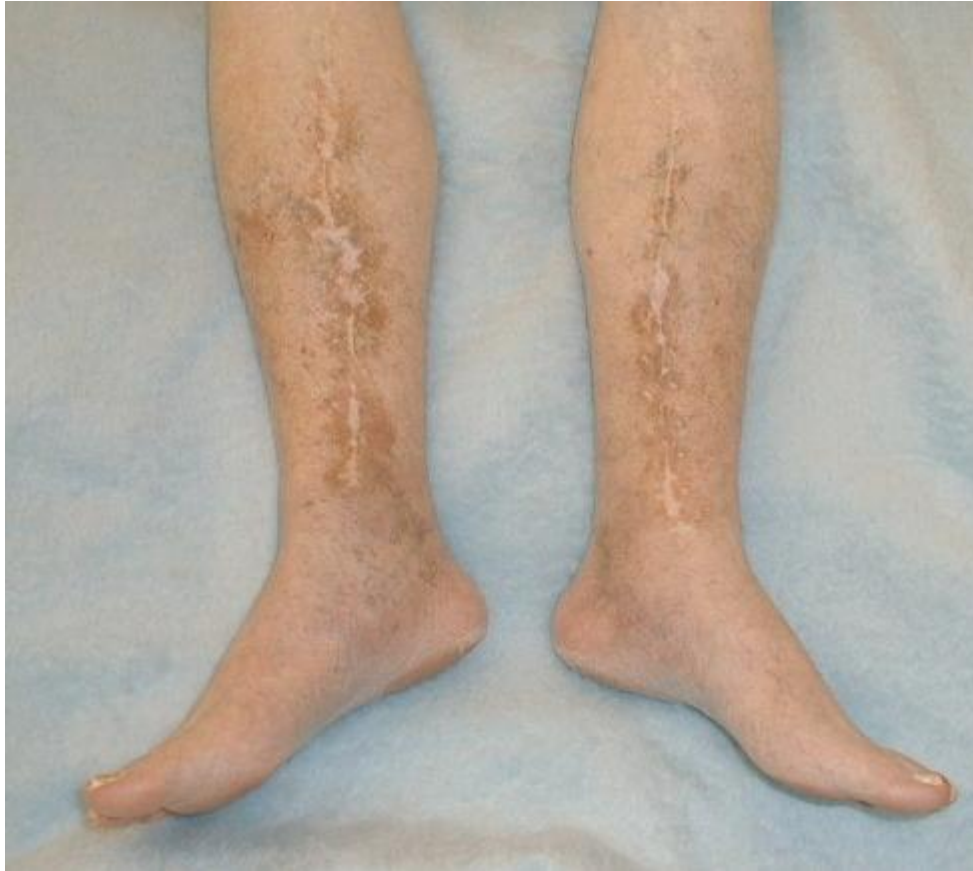

Lower limbs

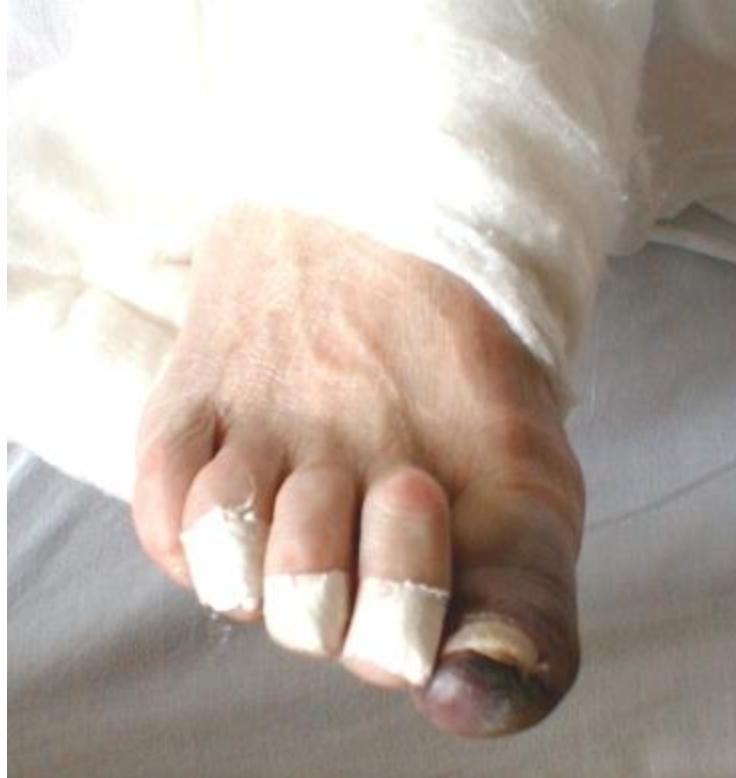Peripheral oedema



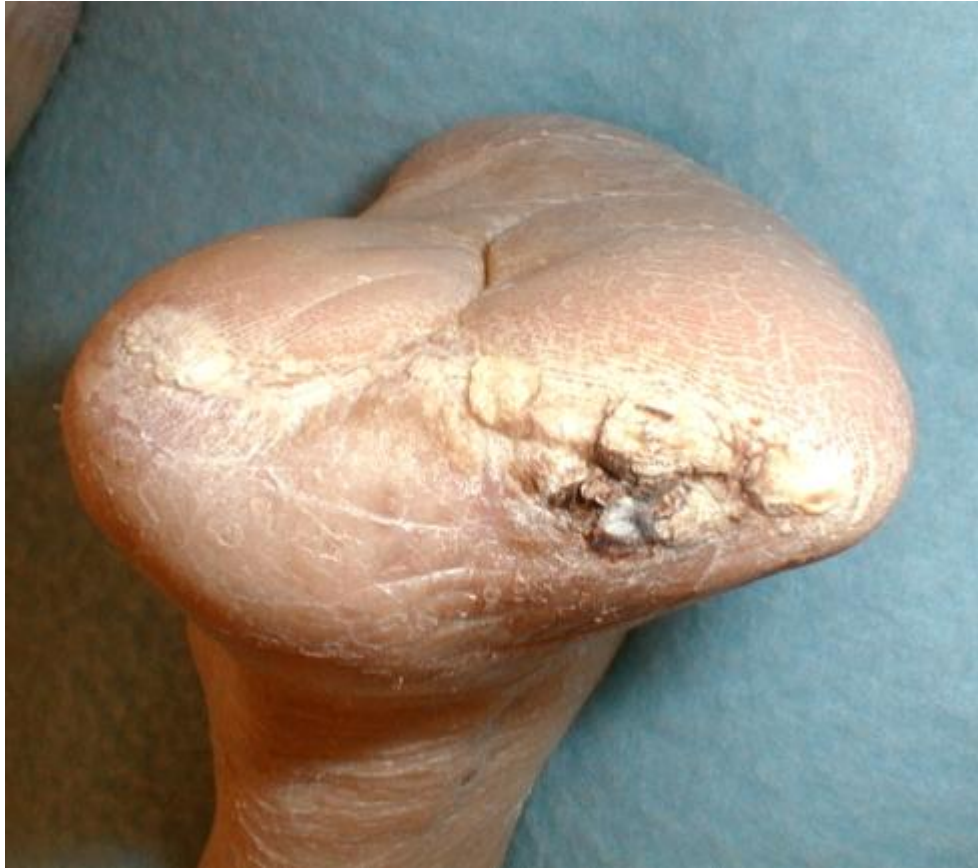Venous grafting scar



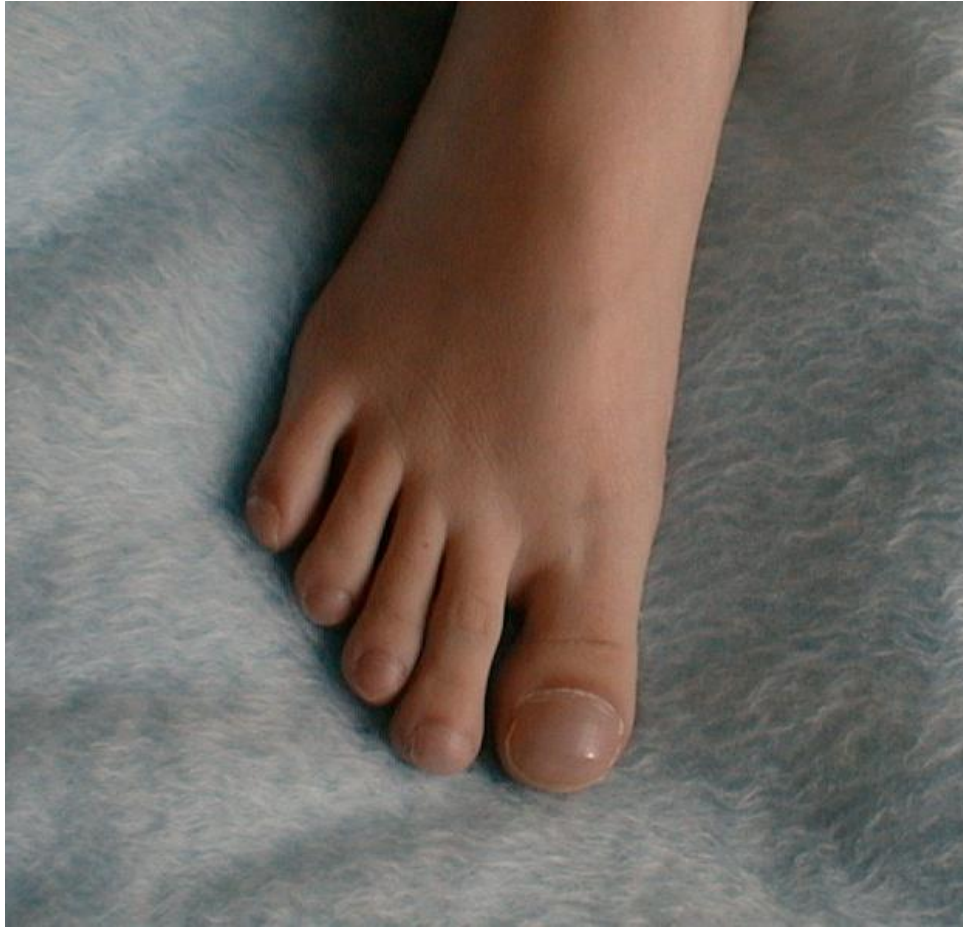Ischaemic toe



Amputated Toes



Digital clubbing



Miscellanea

Starr Edwards Valve

